

## Head Injuries

### Introduction

The motor exam is one of the most important aspects for determining prognosis and role for surgical intervention in head-injured patients. Those patients who follow commands have the best prognosis; however, a subsequent neurological deterioration may indicate an enlarging intracranial hemorrhage or increased intracranial pressure (ICP) with brainstem compression. Those patients who fail to follow commands, but localize or withdraw to stimuli, may also benefit from neurosurgical intervention. The worst category of patients who demonstrate flexion or extensor posturing less frequently benefit from surgical decompression unless done quickly and appropriately. In the case of a large mass lesion, such as an epidural hematoma, outcome is closely related to timing of decompression, with a steep survival fall-off at times >2 hours.

Any subsequent neurological improvement may indicate salvageability and should prompt reevaluation. In theater, survival of combat-related head-injured patients has been better than expected, compared with traditional civilian literature. This is likely related to the rapid on-site airway and hemorrhage control, with rapid evacuation to in-theater neurosurgeons. Currently, US/coalition military patients presenting with a Glasgow Coma Scale (GCS) score of 3–5 have a 35% survival; those with a GCS score of 6–8 have a 90% survival, with aggressive multimodality care. One-year outcomes of casualties sustaining a gunshot wound to the head in Operation Iraqi Freedom and presenting with a GCS score of 3–5, who were treated with aggressive operative decompression and advanced critical care, have been significantly better than reported in civilian literature. Of survivors in this group, 55% of these patients had a 1-year Glasgow Outcomes Score (GOS) of  $\geq 4$ . (The GOS is a functional outcomes score ranging from 1 to 5, with 1 being dead; a GOS of 4 is independent, but disabled.)

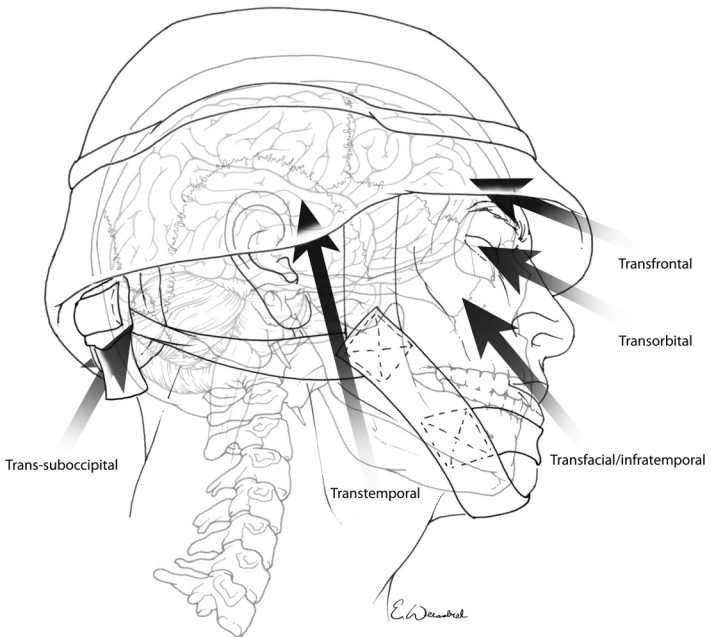
**Neurosurgical damage control includes early intracranial pressure control (which may include surgical decompression); cerebral blood flow preservation; and prevention of secondary cerebral injury from hypoxia, hypotension, and hyperthermia.**

A motor examination of the most salvageable severely brain-injured patients will demonstrate localization to central stimulation. Immediate intubation with adequate ventilation (PaCO<sub>2</sub> of 35) and oxygenation and restoration of intravascular volume are the most critical first-line treatment for a severely head-injured patient. Evacuating to the nearest neurosurgeon, avoiding diagnostic delays, and initiating cerebral resuscitation allow the best chance for ultimate functional recovery. A properly trained surgeon at Role 2 may, at times, find it necessary to surgically intervene should the situation dictate. However, the neurotrauma patient's care should be ideally centralized in the theater of operations, where a neurosurgeon, CT scanner, and fixed air transport are established.

### **Combat Head Injury Types**

- Blunt (closed-head injury).
- Penetrating.
  - Penetrating from fragments.
  - Penetrating from a gunshot wound.
  - Guttering (grooving the skull).
- Primary blast (overpressure central nervous system injuries).
  - A direct injury to the brain or via a force transmitted by the great vessels of the chest to the brain; associated with unconsciousness, confusion, headache, tinnitus, dizziness, tremors, increased startle response, and occasionally (in the most severe forms) increased ICP. Bleeding may occur from multiple orifices, including the ears, nose, and mouth. Alternatively, a blast-injured patient may have no external signs of injury and only subtle signs of cognitive dysfunction in attention, concentration, reaction time, and balance.

A combination of multiple injury types is typically involved in combat-related brain injuries. Those injuries generally involve the face, neck, and orbit; entry wounds may be through the upper neck, face, orbit, or temple (Fig. 15-1).



**Fig. 15-1.** Common vectors of penetrating injury.  
Courtesy of E. Weissbail.

The subocciput, occiput, and retroauricular regions are often overlooked. Injuries to these areas can indicate underlying injury to the posterior fossa, major venous sinus, and vertebral or carotid artery, as fragments pass through the skull base. Reconstructing the fragment path based on a combination of plain films and CT scan can be challenging, but may be beneficial in triage. In transorbital, lateral temporal, or penetrating injuries that cross the midline, an underlying injury to intracranial vessels should be suspected with associated pseudoaneurysms, dissections, or venous sinus injury.

Explosion results in penetrating fragment injury, as well as blunt injury to the brain. Depending on proximity to the explosion, a blast overpressure phenomenon may also result. In a severely

brain-injured patient, more deficits than indicated by the CT scan may be due to underlying injury to brachiocephalic vessels, shear injury, or the late effects of blast overpressure, with resulting delayed cerebral vasospasm. Plain films, more useful in penetrating than in blunt trauma, may reveal a burst fracture of the skull indicating the tremendous force of a penetrating missile. Transventricular bihemispheric fragment tracts portend a poor prognosis. However, bilateral injuries above the level of the ventricles may be better tolerated and respond to bifrontal decompressive craniectomies.

Severe head injuries are often seen in combination with significant chest, abdomen, and extremity injuries. Rapid hemorrhage control, utilizing damage control concepts, is the priority to minimize secondary brain injury. Additionally, many combat penetrating or severe blast injuries include head and neck structures. It is critical for a coordinated plan that includes oral maxillofacial, ENT, and ophthalmology.

### **Traditional Classification of Head Injuries**

- **Open** injuries are more common in combat-injured versus civilian trauma.
- **Closed** injuries are still very common in blunt trauma sustained during combat operations. Blast injury may present as a closed-head injury.
- **Scalp** injuries may be closed (eg, contusion) or open (eg, puncture, laceration, or avulsion).
  - Any scalp injury may be associated with a skull fracture and/or underlying brain injury.
  - Open scalp injuries bleed profusely, even to the point of lethal blood loss, but usually heal well when properly repaired.
- **Skull fractures** may be open or closed, and are described as linear, comminuted, or depressed.
  - Skull fractures are usually associated with some degree of brain injury, varying from mild concussion, to devastating diffuse brain injury, to intracranial hematomas.
  - Open skull fractures are prone to infection if not properly treated.

**Note:** The previous descriptions remain a generalized broad classification that does not always correlate with the prognosis, role for treatment, or level of consciousness. Massive amounts of bleeding and soft-tissue injury can occur in the scalp and superficial cortex with relatively little significant injury to the deep structure of the brain. Alternatively, no external signs of trauma may be present in a patient with a severe “shear” injury to the brainstem, diencephalon, or corpus callosum with a severe comatose state that may persist to a vegetative coma.

### Mechanisms of Injury

- **Primary injury** is a function of the energy transmitted to the brain by the offending agent.
  - Very little can be done by healthcare providers to influence the primary injury.
  - Enforcement of personal protective measures (eg, helmet, seatbelts) by the command is essential prevention.
- **Secondary injury** results from disturbance of brain and systemic physiology by the traumatic event.

**Hypotension and hypoxia are the two most acute and easily treatable mechanisms of secondary injury.**

- Other etiologies include seizures (seen in 30%–40% of patients with penetrating brain injuries), fever, electrolyte disturbances (specifically hyponatremia or hyperglycemia), and infection.
- **All of the previously described conditions can be treated.**
- Elevations of ICP may occur early as a result of a space-occupying hematoma or develop gradually as a result of brain edema or hydrocephalus.
- Normal ICP is 5–15 mm Hg, with normal CPP (CPP = MAP – ICP) usually >70 mm Hg (where CPP = cerebral perfusion pressure; MAP = mean arterial pressure).
- Decreases in perfusion pressure, as a result of systemic hypotension or elevated ICP, gradually result in alteration of brain function (manifested by impairment of

consciousness), and may progress to global brain ischemia and death if untreated.

**Patient Assessment and Triage**

- The most important assessment is the **vital signs**.
- Next is the **level of consciousness**, best measured and recorded by the postresuscitation GCS score (Table 15-1).

**Table 15-1. Glasgow Coma Scale**

Component	Response	Score
Motor response (best extremity)	Obeys verbal command	6
	Localizes pain	5
	Flexion withdrawal	4
	Flexion (decortication)	3
	Extension (decerebration)	2
	No response (flaccid)	1
	<b>Subtotal</b>	<b>1–6</b>
Eye opening	Spontaneously	4
	To verbal command	3
	To pain	2
	None	1
	<b>Subtotal</b>	<b>1–4</b>
Best verbal response	Oriented and converses	5
	Disoriented and converses	4
	Inappropriate words	3
	Incomprehensible sounds	2
	No verbal response	1
	<b>Subtotal</b>	<b>1–5</b>
	<b>TOTAL</b>	<b>3–15</b>

**Note:** Glasgow Coma Scale in intubated patients is followed by a “T,” with a maximum score of 11T (ie, E4M6V1).

- During the secondary assessment, attention should be placed on a complete examination of the scalp and neck. Fragments that enter the cranial vault with a lateral, transorbital, crossing the midline trajectory, or bridging the cranial–cervical junction should be suspected as having associated neurovascular injuries. Wounds are typically contaminated. These wounds should be debrided with removal of foreign material; however,

this should not delay definitive neurosurgical intervention for an underlying hematoma, brainstem compression, or depressed skull fracture that may exist. The scalp should be copiously irrigated clean with control of ongoing scalp hemorrhage. This can be accomplished with a head wrap, scalp clips, or surgical staples; **a meticulous plastic surgical closure before neurosurgical evaluation is not appropriate and should not delay transfer.**

- Triage decisions in the patient with craniocerebral trauma should be made based on first available GCS score (**admission or prehospital**), pupillary reactivity, and available resources.
  - A GCS score of  $\leq 5$  indicates a poor prognosis; however, with aggressive comprehensive treatment, the combat casualty can have a higher survival than standard civilian neurotrauma patients (up to 35%) and higher GOSs. This is particularly true for patients who will have access to further rehabilitative care and higher treatment facilities. If triaged to an expectant category, they should be reassessed.
  - A GCS score of  $\leq 9$  indicates that a casualty may do well if managed appropriately.
    - ◆ In general, neurologically stable patients with penetrating head injury can be managed effectively in the ICU with airway and ventilatory support, antibiotics, and anticonvulsants while awaiting surgery.
    - ◆ An exception to this would be a clinically deteriorating patient (ie, a suspected large hematoma—this should be considered a surgical emergency).
  - **Casualties with a GCS score of 6–8 can be the most reversible, with in-theater neurosurgical management involving control of ICP and preservation of cerebrospinal fluid. Treatment decisions may have to take into account access to further rehabilitative and supportive care.**
  - **Casualties requiring evacuation to neurosurgical care should not have transportation delayed for surgical management of injuries that are not life-threatening.**
- **Pupillary reactivity.**
  - Be aware that eye injuries are common with associated intracranial injuries and can therefore affect pupillary exam.

- A single dilated or nonreactive pupil adds urgency and implies the presence of a unilateral space-occupying lesion with secondary brain shift. Immediate surgery may be indicated.
- The presence of bilateral dilated or nonreactive pupils is a dismal prognostic sign in the setting of profound alteration of consciousness.

**A single dilated or nonreactive pupil adds urgency and implies the presence of a unilateral space-occupying lesion with secondary brain shift. Immediate surgery may be indicated. Transportation to neurosurgical care should not be delayed for treatment of injuries that are not life-threatening.**

● **Radiographic evaluation.**

- CT scanners are often available at Role 3 medical treatment facilities.
  - ◆ Noncontrast **CT is the definitive radiographic study in the evaluation of acute head injury**, and should be used liberally, as it greatly improves diagnostic accuracy and facilitates management. A CT angiogram should be performed after noncontrast CT in those cases wherein a major neurovascular injury may have occurred, including dural venous sinus injury, traumatic pseudoaneurysm, or dissection.
- Skull radiographs still have a place in the evaluation of head injury (especially penetrating trauma).
  - ◆ In the absence of CT capability, AP and lateral skull radiographs help to localize foreign bodies in cases of penetrating injuries and can also demonstrate skull fractures.
  - ◆ This can help direct otherwise “blind” surgical intervention initially to the side of the head where the fracture is identified.
- Closed-head injury can be associated with injury of the cervical spine.
  - ◆ Survivable cervical spine injury occurs in less than 2% of isolated penetrating head injury in combat trauma.



- ◆ In blunt trauma (blast injury included), assume the presence of cervical spine injury and keep the cervical spine immobilized with a rigid collar until a standard CT of the cervical spine can be obtained. The CT scan should be of fine cuts (3 mm), and with sagittal and coronal reconstructions. AP, lateral, and open-mouth radiographs do not definitively clear a spine for bony injury in the obtunded patient, but may be of assistance when a CT scan is not available. (See Joint Theater Trauma System [JTTS] Clinical Practice Guidelines.)
- ◆ In penetrating head trauma that may involve the cervical spine, CT scan should also be performed when the patient is obtunded or presents with motor or sensory deficits.

## Management

### ● Medical.

- Primary tenets are basic, but vital: protect the airway, ensure adequate ventilation, and assess and treat for shock (excessive crystalloid administration should be avoided).
- In general, patients with a GCS score of  $\leq 13$  should be managed in a monitored setting.
- **Management should be directed toward preventing secondary brain injury.**
  - ◆ Avoid cerebral hypoxia by maintaining the  $\text{PaO}_2 > 80$  mm Hg or oxygen saturation  $> 93\%$ .
  - ◆ Avoid cerebral hypoperfusion by keeping  $\text{SBP} > 90$  mm Hg.
  - ◆ Avoid vasoconstriction or vasodilation by maintaining the  $\text{PaCO}_2$  between 35 and 40 mm Hg.
  - ◆ The head of the bed should be elevated  $> 30^\circ$ . (Use reverse Trendelenburg position of the bed if the thoracolumbar spine is unable to be cleared.)
  - ◆ The neck should be positioned in the midline and the cervical collar loosened to prevent occlusion of the internal jugular veins (and subsequent elevation of the ICP). Avoid placement of the internal jugular vein central line that may induce jugular vein thrombosis and subsequent increased ICP.
  - ◆ Sedate the severely brain-injured patient with short-acting agents (to allow frequent neuro exams) to

limit stimulation and to avoid dyssynchrony with the ventilator—both leading to ICP elevation. (Propofol has been the preferred early sedating agent. Be cautious of hypotension with its use.)

- ◆ Early initiation of hyperosmolar therapy with 3% saline is recommended for a GCS score of <12. May be given as a 250-mL bolus, followed by an infusion. The goal is serum sodium of 145–155 mEq/L with serum Osm <330 mmol/L. (See JTTS Clinical Practice Guidelines on Severe Head Trauma.)
- ◆ Administer Cefazolin 2 grams every 6–8 hours for 5 days in patients with penetrating injuries. (Vancomycin is a second-line alternate.)
- ◆ Administer 5 days of Metronidazole for grossly contaminated wounds or those open wounds whose treatment has been delayed more than 18 hours.
- ◆ Phenytoin should be administered in patients with penetrating head injury or those with suspected or demonstrated significant intracranial blood volume (>1 cm) on CT scan. Use a 17-mg/kg load, in a normal saline piggyback and given over 20–30 minutes (no more than 50 mg/min, because rapid infusion may cause cardiac conduction disturbances).
  - ◇ A maintenance dose of 300–400 mg/day, either in divided doses or once before bedtime, should be adequate to maintain a serum level of 10–20 mg/L.
- ◆ Alternatively, a Levetiracetam (Keppra) load of 1,500 mg IV with 1,000 mg bid has been effective with a lower cross-reactivity with other medications, including antibiotics, and less side-effect profile than phenytoin.
- ◆ Measure serum chemistries daily to monitor for hyponatremia or severe hypernatremia (>160 mEq/L). This should be done q6h if 3% NaCl or mannitol has been utilized.
- ◆ Treat initial coagulopathy aggressively (goal INR <1.4).
- ◆ Hyperglycemia and hypoglycemia should be treated.
- ◆ Blast overpressure central nervous system injuries.
  - ◇ Supportive medical therapy is usually sufficient. Only in rare cases is an ICP monitor, ventriculostomy, or

cranial decompression necessary. Delayed intracranial hemorrhages have been reported. Additionally, these patients have a higher susceptibility to subsequent injury and should be evaluated at a Role 4 medical treatment facility. Repetitive injury and exposure to blast overpressure may result in irreversible cognitive deficits.

- ◆ **Monitoring of ICP is recommended for all patients with a GCS score of  $\leq 8$  or for those patients undergoing intertheater aeromedical evacuation, wherein serial neurological examination is needed (in essence, it is an adjunct to a neurological examination).**
  - ◇ An intraparenchymal ICP monitor (ICP EXPRESS by Codman is the US Air Force aeromedical-approved device) can be placed with relative ease into the brain parenchyma and gives an accurate reflection of the ICP. Cerebrospinal fluid is not able to be withdrawn.
  - ◇ A ventriculostomy is preferred in a comatose patient at a Role 3 medical treatment facility, since both the measurement and treatment of increased ICP can be performed. (A simple, fluid-coupled monitor ensuring that no pressurized bag is paired with the transducer.)
    - Administer prophylactic antibiotic (Cefazolin 2 grams) prior to insertion.
    - Make an incision just at or anterior to the coronal suture, approximately **2.5–3 cm** lateral to the midline (Fig. 15-2a,b).
    - A twist drill craniostomy is performed, the underlying dura is nicked, and a ventricular catheter is placed into the frontal horn of the lateral ventricle (encountered at a depth of 5–6 cm) (Fig. 15-2b,c). Catheter should be directed toward the medial epicanthis on the coronal plane and toward the tragus in the sagittal plane.
    - Even small ventricles can be easily cannulated by aiming the tip of the catheter toward the nasion in the coronal plane.
    - Antibiotic-impregnated ventricular catheters are highly preferable; acceptable substitutes are an 8 Fr Robinson catheter or pediatric feeding tube.

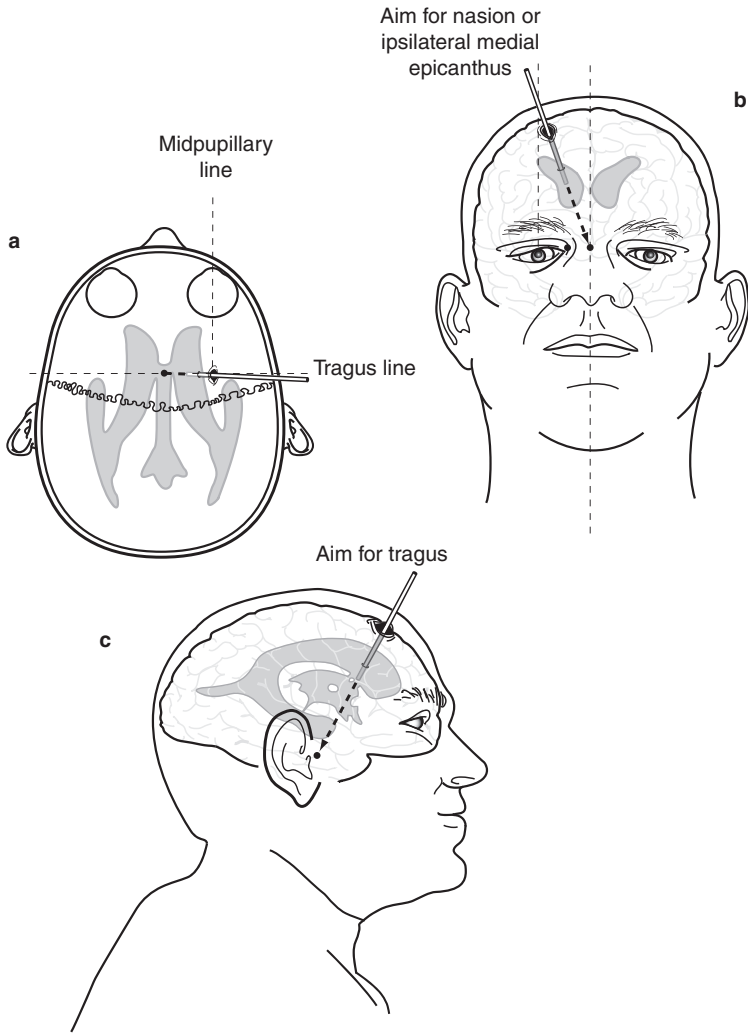
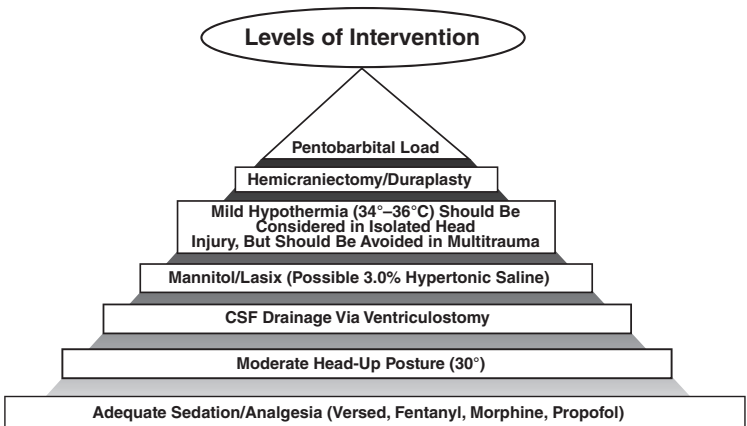


Fig. 15-2. Placement of the intracranial ventricular catheter.

- A key feature of this technique is to tunnel the drain out through a separate incision 2–3 cm from the primary one, thus reducing the risk of infection.

- ◇ A sustained ICP >20 mm Hg for more than 5 minutes should be treated (Fig. 15-3). (See JTTs Clinical Practice Guidelines.)
- ◆ Once an ICP monitor is in place, calculate a CPP (CPP = MAP – ICP).
  - ◇ The goal of management is to maintain a CPP of >60 mm Hg.
  - ◇ Intravascular volume status should be assessed, with euvolemia being the goal. This is difficult in the deployed setting and one reason to avoid mannitol. A central venous pressure (CVP) of 8–10 mm Hg in a young patient on normal levels of positive end-expiratory pressure (5 cm H<sub>2</sub>O) should be suggestive of an adequate volume. Values less than this may indicate a need for additional fluid resuscitation. If additional blood is warranted, ensure that the packed red blood cell unit is the freshest available to facilitate brain tissue oxygenation.
  - ◇ If CPP remains low after adequate fluid resuscitation and reassessment for other sources of hypotension (bleeding, pharmacological, etc), initiate a vasopressin infusion at 0.04 units/min. If CPP remains low, begin a vasopressor, such as phenylephrine or norepinephrine



**Fig. 15-3.** Levels of intervention to reduce ICP. CSF: cerebrospinal fluid.

(norepinephrine should begin at 5 mg/kg/min and titrate as needed; maximum dose being 20 mg/kg/min). If CPP is low, the initiation of a vasopressor to support CPP is warranted while the other measures previously mentioned can be performed.

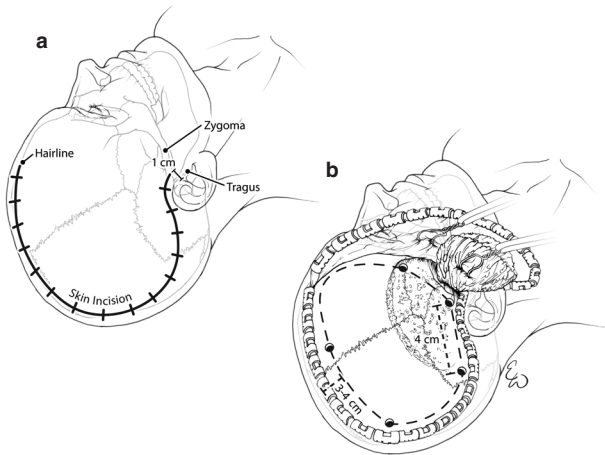
- Sedation, head elevation, neck midline, and cervical collar loosened.
- Cerebrospinal fluid drainage to an ICP of 20 mm Hg if a ventricular catheter is in place.
- **Mild hyperventilation to a PaCO<sub>2</sub> of 30–35 mm Hg ONLY AS A BRIDGING MANEUVER until other measures take effect.** (Prolonged levels below this are deleterious, as a result of small vessel constriction and ischemia.) Once the acute ICP elevation is treated, ventilation should then be titrated to a PaCO<sub>2</sub> of 35–40 mm Hg.
- Hyperosmolar therapy should be initiated with a 250-mL bolus of 3% NaCl, followed by an infusion of 50 mL/h. If 3% NaCl has already been initiated and serum sodium levels remain below 150, consider a second bolus at this time. (See JTTS Clinical Practice Guidelines.)
- Normothermia should be maintained. Uncover the patient, use fans, apply ice to the groin and axilla. Fever will lead to increased metabolic activity of the brain, increased ICP, and increased vasospasm. At Role 3/4, this can be performed with surface cooling gel pads with a closed-loop automated system calibrated with a Foley catheter thermistor.
- Utilize pharmacological paralysis if heavy sedation is not effective or as needed for transport (Vecuronium 5–10 mg IV PRN or as a drip for longer acting use). Maintain paralysis by assessing with a neurostimulation device to a “train of 4” (1/4) to prevent overmedication or undermedication.
- **Any patient who develops intracranial hypertension or deteriorates clinically should undergo prompt head CT to reassess for need for surgical intervention.**

- Refractory intracranial hypertension may be managed with an initial bolus of 1 g/kg of **mannitol** and intermittent dosing of 0.25–0.5 g/ kg q4h as needed.
  - Aggressive treatment with mannitol should be accompanied by placement of a CVP line because hypovolemia may ensue.
  - Serum osmolality is not able to be measured in the deployed setting, making mannitol’s use complex and further management more difficult. **It can be used to “buy time” en route to the neurosurgeon.**
  - **Do not use mannitol in hypovolemic or under resuscitated patients because it will produce hypotension.**
- Pentobarbital coma can be used in refractory ICP elevation, but has been essentially replaced by decompressive craniectomy. Pentobarbital coma requires a CVP monitor and ideally EEG to titrate dose to burst suppression. Duration of therapy is usually limited to 72 hours. (**Load:** 2.5 mg/kg q15 min × 4 doses, 10 mg/kg/h ggt × 3 hours; **Maintenance:** 1.5 mg/kg/h; ideally, one would check a level and decrease maintenance if >5 mg% or becomes hypotensive.) The pulmonary, infectious, and cardiac adverse effects have limited its utility and recent application.
- At Role 4, mild hypothermia (32°–34°C) may be considered in isolated head injury, unresponsive to other measures. It should be avoided in the multisystem trauma patient. Care should be taken to prevent rapid unintentional re-warming because it can cause a secondary brain injury.
- Surgical.
  - Goals: Stop hemorrhage, relieve/prevent intracranial hypertension, and prevent infection.
  - **ROLE 2:** Indications for emergent exploration and a damage control craniectomy (**must be done in consultation with regional neurosurgeon, if available**). These may be

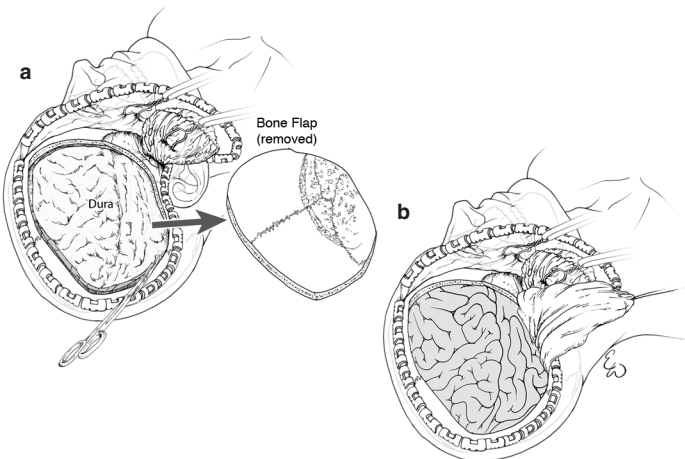
“presumed” at a Role 2 medical treatment facility, because CT scan will rarely be available.

- ◆ Presumed space-occupying lesions with neurological deterioration (eg, acute epidural hematoma). This may be suspected with an unreactive/dilated pupil, especially when associated with contralateral hemiparesis.
- ◆ Compound depressed fracture with significant neurological deterioration.
- ◆ Penetrating injuries with significant neurological deterioration.
- Relief of ICP with hemicraniectomy.
  - ◆ A large trauma flap should be planned for the evacuation of a mass lesion with significant underlying edema in the supratentorial space.
  - ◆ The common mistakes are failure to make the bone flap large enough due to a misplacement of the burr holes, not anterior enough, not posterior enough, or inadequate temporal bone removal at the skull base (Fig. 15-4).
- Shave hair widely and scrub and paint the scalp with betadine.
- General anesthesia.
- Administer empiric antibiotics (Cefazolin: 2 grams).
- Positioning can be adequately managed with the head in a doughnut or horseshoe-type head holder. The head will be turned away from the side of the craniectomy.
- Make a generous scalp incision to create an adequate flap (Fig. 15-5a).
- The flap should extend a minimum of 4 cm posterior to the external auditory canal and 2–3 cm off midline. Exposing the frontal, temporal, and parietal lobes allows for adequate cerebral swelling and avoids brain herniation at the craniectomy edge.
- Ensuring that decompression in adults measures 15 cm in the AP dimension and 12 cm from the middle cranial fossa to the vertex is essential.
  - ◆ The flap should have an adequate pedicle to avoid ischemia; preservation of the superficial temporal artery should be performed.
  - ◆ Scalp hemorrhage can be controlled with a running, locking suture or Raney clips.





**Fig. 15-4.** Cranial landmarks and location of standard burr holes. Courtesy of E. Weissbial.



**Fig. 15-5.** Craniectomy flap. Courtesy of E. Weissbial.

- ◆ Retraction of the scalp flap over a rolled laparotomy sponge will avoid kinking the flap, which also may lead to ischemia. Avoid placement of the sponge over the globe, however, since this can result in increased intraocular pressure and therefore ICP and, in rare cases, blindness.
- ◆ **Burr holes alone are inadequate to treat acute hematomas**, but are potentially of diagnostic utility in the absence of a CT scanner. Exploratory burr holes may miss subfrontal or interhemispheric hematomas (Fig. 15-6).

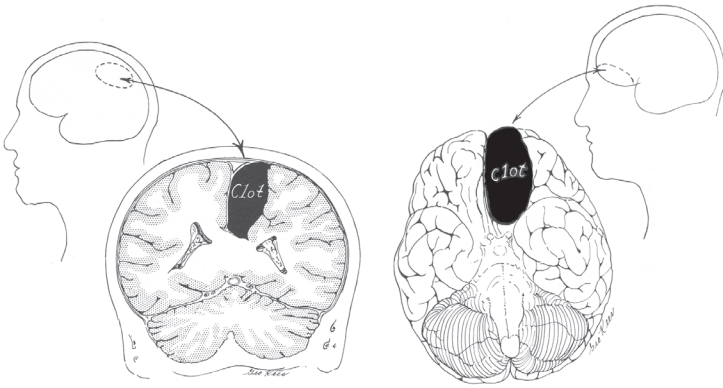


Fig. 15-6. Hematomas missed with routine exploratory burr holes.

- ◆ The bone work may be done with a Hudson brace and Gigli saw (passed beneath the cranium with the help of a Gigli saw passer or tonsil clamp), though a power craniotome is certainly preferable if available (see Fig. 15-5a).
- A large dural opening should be created, using the entire expanse of the cranial opening with enough edge (~5 mm) left to close the dura at a later time.
  - ◆ The base of the dural opening should be on the side near any neighboring major venous sinus to avoid injury to large draining veins and aggravation of cerebral edema.
- For the **damage control craniectomy** by the general surgeon, removal of devitalized tissue should be deferred to the neurosurgeon, as long as bleeding can be controlled.

- ◆ The hematoma should be gently evacuated with a combination of irrigation and mechanical removal. Copious irrigation will help to “float” bone fragments to the surface for easier removal.
- ◆ Thrombin-soaked gel foam may be the best and easiest adjunct measure for bleeding control. Bipolar cautery is ideal, or unipolar electrocautery with forceps, clips, and suture may be used. Avoid injury to the large midline sagittal sinus.
- ◆ The dura should be left open.
- ◆ The scalp can be closed full thickness with a running nylon suture.
- Skull flap (the removed portion of the skull) management has been evolving.
  - ◆ For local nationals, options include: wash aggressively and place the skull flap in the abdominal-wall fat pocket, freezer storage (if available) of the bone flap, hinge cranioplasty.
  - ◆ Discard the flap in US patients. Reconstruction can be performed using titanium, methyl methacrylate or acrylic at a later date.
- Apply a loose dressing using roller bandages around the entire head.
- Evacuate patient to neurosurgical care as soon as possible.
- **ROLE 3:** Indications for emergent surgical intervention by neurosurgeon include:
  - ◆ Space-occupying lesions with neurological changes (eg, acute subdural/epidural hematoma, abscess).
  - ◆ Intracranial hematoma producing a >5 mm midline shift or similar depression of cortex.
  - ◆ Compound depressed fracture with neurological changes.
  - ◆ Penetrating injuries with neurological deterioration.
- A similar procedure will be followed, but with the addition of the following:
  - ◆ Relief of ICP with wide hemicraniectomy/duraplasty/ventriculostomy.

- ◆ A capacious duraplasty should be constructed with a subdural ICP/ventricular catheter in place, allowing monitoring and drainage from the injured hemisphere.
- ◆ For unusual positioning of the head, so as to gain access to the subocciput, a standard 3-point Mayfield fixation device may be useful.
- Approach to **penetrating injury with neurological changes** is aimed at removal of devitalized brain and easily accessible foreign bodies.
  - ◆ Perform copious irrigation with an antibiotic solution (eg, Bacitracin) and a concerted attempt made to achieve watertight skin closure.
  - ◆ Tension-free scalp closure is also essential, but replacement of multiple skull fragments in an attempt to reconstruct the skull defect is not appropriate if other options for reconstruction are available.
    - ◇ Excellent results can be achieved with cranioplasty after evacuation from theater and a sufficient delay to minimize risk of infection.
- An expansion duraplasty should always be performed. A commercial dural substitute may be available; otherwise, pericranium, temporalis fascia, or tensor fascia lata may be used. There is no need to perform a water-tight dural repair.
- Tack-up sutures should be placed around the periphery (no central tack-ups in the absence of a bone flap) of the dural exposure to close the dead space and discourage postoperative epidural hematoma formation.
- The galea of the scalp should be closed separately with an absorbable suture and staples used to close the skin.
  - ◆ A single layer closure with heavy monofilament nylon is acceptable, but should definitely include the galea, with the sutures remaining in place for at least 14 days.
  - ◆ A subgaleal or epidural drain should be used at the discretion of the surgeon.
- Apply a noncompressive dressing using roller bandages around the entire head.
- Obtain a postoperative CT scan.

**Note: Injuries that include the frontal sinus, anterior skull base, and orbital roof should undergo early repair, which includes frontal sinus exenteration; cranialization of the frontal sinus; obstruction of the nasofrontal duct; and a multilayer closure with pericranium, fat, fascia, and autologous split-thickness bone.**

### Evacuation of the Head-Injured Patient

- A postoperative craniotomy/craniectomy patient should ideally first be observed for 12–24 hours prior to transport. Evacuating immediately may lead to the inability to treat delayed, postoperative hematomas that may occur.
  - All patients with a GCS score of  $\leq 12$  are likely to benefit from intubation prior to evacuation.
  - Patients with a GCS score of  $\leq 8$  or patients who cannot be awakened en route by the transport team (each hour) will require ICP monitoring.
  - Arterial catheterization is necessary in patients where CPP monitoring is critical.
  - Patients with intracranial pathology should be neurosurgically “optimized” on the ground prior to departure (eg, placement of a ventriculostomy, wide craniectomy, or evacuation of a hematoma).
  - The ICP monitor should be placed, position confirmed, secured, and working prior to departure. A ventriculostomy gives the transport team the therapeutic option of cerebrospinal fluid drainage for an elevated ICP.
  - The critical care evacuation team must be confident in its ability to medically treat increased ICP, treat related complications (eg, diabetes insipidus with DDAVP [Desmopressin]; hyperthermia; and seizure), and troubleshoot the ventriculostomy.
  - In addition to all standard preevacuation preparation (see Chapter 4, Aeromedical Evacuation):
    - ◆ Drain the ventriculostomy; avoid laying it down flat because the vent filter may become moist and lead to an “air-lock.” Venting the tubing filter can be performed with a clean 21-gauge needle, if needed.

- ◆ If a head-injured patient deteriorates in flight and is not already intubated, intubation should be considered.
- ◆ Medical management of ICP in flight should follow the same algorithm as previously described; however, repeat CT scanning or return to the operating room are no longer an option.
- ◆ Loading a patient head-of-bed toward the front of the aircraft limits the effect of takeoff and a “nose up” attitude of the aircraft while in flight (3% in the C-17) on ICP.

**For Clinical Practice Guidelines, go to  
[http://jts.amedd.army.mil/index.cfm/PI\\_CPGs/cpgs](http://jts.amedd.army.mil/index.cfm/PI_CPGs/cpgs)**